

Anti-*Helicobacter pylori* Properties of GutGard™

Jae Min Kim^{1,2}, Hong Mei Zheng¹, Boo Yong Lee³, Woon Kyu Lee^{1,2}, and Don Haeng Lee¹

¹National Center of Efficacy Evaluation for the Development of Health Products Targeting Digestive Disorder, Inha Hospital, Incheon 400-712, Korea

²Laboratory of Developmental Genetics, Inha University School of Medicine, Incheon 400-712, Korea

³Department of Food Science & Biotechnology, CHA University, Gyeonggi 487-010, Korea

ABSTRACT: Presence of *Helicobacter pylori* is associated with an increased risk of developing upper gastrointestinal tract diseases. Antibiotic therapy and a combination of two or three drugs have been widely used to eradicate *H. pylori* infections. Due to antibiotic resistant drugs, new drug resources are needed such as plants which contain antibacterial compounds. The aim of this study was to investigate the ability of GutGard™ to inhibit *H. pylori* growth both in Mongolian gerbils and C57BL/6 mouse models. Male Mongolian gerbils were infected with the bacteria by intragastric inoculation (2×10^9 CFU/gerbil) 3 times over 5 days and then orally treated once daily 6 times/week for 8 weeks with 15, 30 and 60 mg/kg GutGard™. After the final administration, biopsy samples of the gastric mucosa were assayed for bacterial identification via urease, catalase and ELISA assays as well as immunohistochemistry (IHC). In the Mongolian gerbil model, IHC and ELISA assays revealed that GutGard™ inhibited *H. pylori* colonization in gastric mucosa in a dose dependent manner. The anti-*H. pylori* effects of GutGard™ in *H. pylori*-infected C57BL/6 mice were also examined. We found that treatment with 25 mg/kg GutGard™ significantly reduced *H. pylori* colonization in mice gastric mucosa. Our results suggest that GutGard™ may be useful as an agent to prevent *H. pylori* infection.

Keywords: *H. pylori*, *G. glabra*, gastric mucosa, colonization

INTRODUCTION

Helicobacter pylori (*H. pylori*) is a gram-negative spiral, or helical, shaped bacteria inhabiting the gastric epithelial cells (1). Remarkably, about half of the world human population is reportedly infected by *H. pylori*. The prevalence rates of *H. pylori* are highly variable in different regions of the industrialized and developing countries ranging from nearly 70% to greater than 95% (2). *H. pylori* is associated with an increased risk of developing upper gastrointestinal tract diseases, namely peptic ulcer (3,4), gastric carcinoma (5), and gastric MALT lymphoma (6). World Health Organization (WHO) classified *H. pylori* as a type I carcinogen for gastric carcinoma (7). Maastricht III Consensus and American College of Gastroenterology recommend standard triple therapy (a proton pump inhibitor (PPI), clarithromycin, and amoxicillin or metronidazole) and bismuth-based quadruple therapy (bismuth with PPI and two antibiotics) as first line treatments in subjects infected with *H. pylori* (8,9). However, these therapies have not been shown success-

fully and effectively. Despite the large number of studies, identifying an optimal regimen for *H. pylori* therapy still remains a challenging clinical problem. Based on systematic reviews and meta-analysis reports, the primary cause of therapeutic failure is *H. pylori* resistance to the antibiotics (10,11). Even though antibiotic resistance can be detected using molecular test systems, this does not provide the basic solution to solve this problem (12,13). Besides resistance, adverse effects and poor patient compliance limit the efficacy of these regimens; hence, alternative remedies are requested constantly.

With the growing popularity for naturally occurring medicinal plants, herbal preparations have been evaluated for the management of *H. pylori*. One medicinal plant that holds promise for *H. pylori* management is licorice (14). Licorice (*Glycyrrhiza glabra* Linn; Family: Leguminosae) has been used in traditional ways for several centuries. The roots and rhizomes of *G. glabra* have been reported to contain antipyretic, antimicrobial, hepatoprotective, antioxidant, antiadhesive, anxiolytic, expectorant, laxative and diuretic effects (15,16). In addi-

Received April 1, 2013; Accepted April 15, 2013

Correspondence to Woon Kyu Lee, Tel: +82-32-890-1182, E-mail: wkleee@inha.ac.kr

Copyright © 2013 by The Korean Society of Food Science and Nutrition. All rights Reserved.

© This is an Open Access article distributed under the terms of the Creative Commons Attribution Non-Commercial License (<http://creativecommons.org/licenses/by-nc/3.0>) which permits unrestricted non-commercial use, distribution, and reproduction in any medium, provided the original work is properly cited.

tion, *G. glabra* also has anti-viral, anti-inflammatory, anti-cancer and anti-ulcer activities (17). *G. glabra* was reported to exhibit anti-microbial activity against several gram negative and gram positive bacterial strains including *H. pylori* (18). Besides these properties, licorice also demonstrated beneficial effects on *H. pylori* through its anti-*H. pylori* property (16). Curative effect of deglycrrhizinated licorice (DGL) on ulcer has been reported *in vivo* as well as in clinical studies (19,20).

GutGard™ is a standardized extract from the deglycrrhizinated root of *G. glabra* and its safety and efficacy has been evaluated in several studies. *In vitro* battery of genotoxicity tests showed no evidence of clastogenic and mutagenic effects. In an acute oral toxicity study, GutGard™ was found to be safe up to 5,000 mg/kg rat body weight (21). A randomized, double-blind, placebo-controlled clinical study reported significant decrease in symptoms scores of functional dyspepsia without any major related adverse effects (22). Furthermore, GutGard™ also exhibited anti-ulcer activity in a dose dependent manner along the 12.5, 25, and 50 mg/kg dose levels in pylorus ligation, cold-restraint stress, and indomethacin induced ulcer of albino Wistar rats (23). Therefore, the aim of the present study is to investigate the anti-*H. pylori* properties of GutGard™ using animal models infected with the bacteria.

MATERIALS AND METHODS

Chemicals

GutGard™ is a flavonoid rich, standardized extract of *Glycyrrhiza glabra* developed by Natural Remedies, Pvt. Ltd, Bangalore. GutGard™ was standardized to the content of the following bioactive constituents: glabridin ($\geq 3.5\%$ w/w), glabrol ($\geq 0.5\%$ w/w), eicosanyl caffeinate ($\geq 0.1\%$ w/w), docosyl caffeate ($\geq 0.1\%$ w/w) and total flavonoids ($\geq 10.5\%$ w/w). GutGard™ was further standardized using the *in vitro* 1,1-diphenyl-2-picrylhydrazyl (DPPH) radical scavenging assay ($IC_{50} < 75 \mu\text{g/mL}$). All other chemicals were purchased from Sigma-Aldrich (St. Louis, MO, USA).

H. pylori strain and culture

The *H. pylori* strain SS1 (HPKTCC B0890) was obtained from the *H. pylori* Korean Type Culture Collection (HPKTCC, KNMRRC), and cultured on 10% bovine serum Muller-Hinton agar plates supplemented with 6 $\mu\text{g/mL}$ vancomycin, 8 $\mu\text{g/mL}$ amphotericin B, and 10 $\mu\text{g/mL}$ nalidixic acid in an anaerobic chamber with 10% CO_2 , 5% O_2 and 85% N_2 at 37°C with enough humidity (Sanyo, Osaka, Japan). The strain was identified on the basis of colony appearance, gram staining, and positive

reactions in biochemical tests (urease and catalase).

Animals

Specific pathogen-free 6-week-old male Mongolian gerbils and male C57BL/6 mice were obtained from Central Lab Animal Inc. (Seoul, Korea). Animal care and all experimental procedures were conducted in accordance with the approval and guidelines of the INHA Institutional Animal Care and Use Committee (INHA IACUC) at the Inha University Medical School (approval ID: INHA 120220-130). The animals were fed standard rat chow and tap water *ad libitum*, and maintained under a 12 h dark/light cycle at 21°C. For biosafety, the investigators were fully protected with sterilized clothes, masks and gloves based on Standard Operation Procedures (SOP).

H. pylori infection in Mongolian gerbils

Following a pre-feeding period of 1 week, 50 gerbils were randomly divided into the following 5 groups (Fig. 1A): uninfected (Group 1), *H. pylori* infection alone (Group 2), and *H. pylori* infection+GutGard™ at 15 mg/kg (Group 3), 30 mg/kg (Group 4), and 60 mg/kg (Group 5) with 10 gerbils in each group. The infection was induced as follows: after 24-hour fasting, the animals were inoculated 3 times by oral gavage with *H. pylori* SS1 (2×10^9 CFU [colony-forming units]/gerbil) suspended in 500 μL PBS over 5 days. Mongolian gerbils inoculated with SS1 or PBS were kept separately, with free access to water and food. Groups 3, 4 and 5 were orally treated with GutGard™ at the dose levels of 15, 30 and 60 mg/kg, respectively, once daily for 6 times every week over 8 weeks, while Groups 1 and 2 received intragastric administration of sterile tap water after the final inoculation of *H. pylori*.

H. pylori infection in C57BL/6 mice

Following a pre-feeding period of 1 week, 30 mice were randomly divided into the following 3 groups (Fig. 1B): uninfected (Group 1), *H. pylori* infection alone (Group 2) and *H. pylori* infection+GutGard™ 25 mg/kg (Group 3) with 10 mice in each group. The infection was induced as follows: the mice were fasted 4 hours before inoculation. Specific pathogen-free C57BL/6 male mice were inoculated 3 times by oral gavage with *H. pylori* SS1 (2×10^9 CFU/mouse) suspended in 500 μL PBS over 5 days. This procedure followed a well-established mouse model of *H. pylori* infection (24). Mice inoculated with SS1 or PBS was kept separately, with free access to water and food. Group 3 mice were orally treated with GutGard™ (25 mg/kg) once daily for 6 times every week for 3 weeks, while Groups 1 and 2 received intragastric administration of sterile tap water after the final inoculation of *H. pylori*.

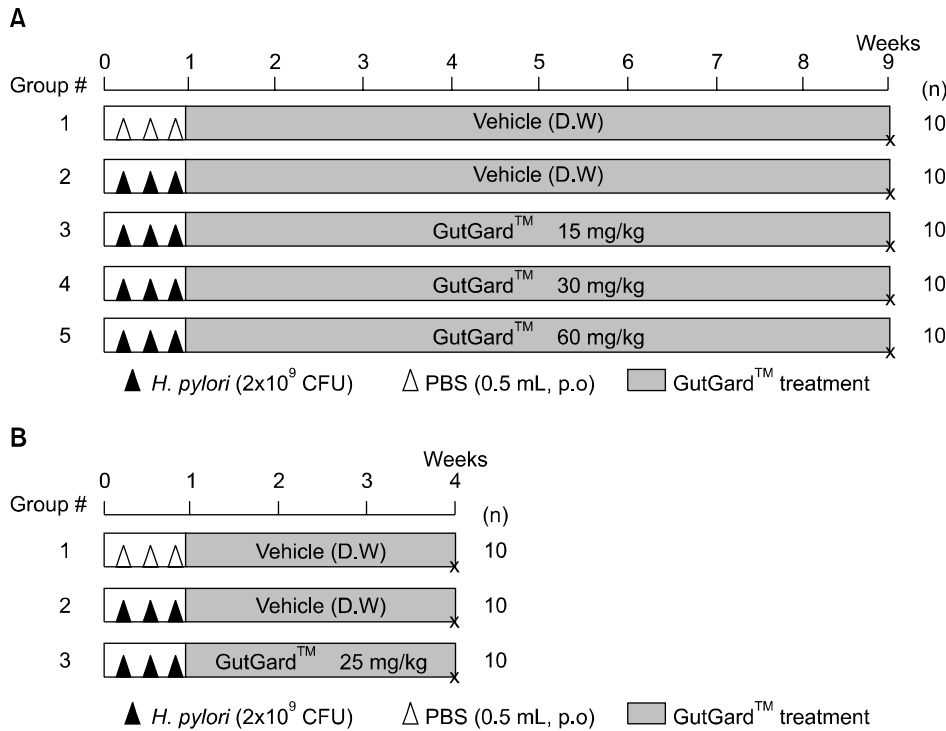


Fig. 1. Experimental schedule for *in vivo* evaluation of efficacy of GutGard™ on anti-*Helicobacter pylori*. (A) Time-points of *H. pylori* infection and GutGard™ treatment in Mongolian gerbils. Gerbils in Groups 2, 3, 4 and 5 were orally administered *H. pylori* (2×10^9 colony-forming units (CFU)) three times over 5 days. After *H. pylori* inoculation, gerbils in Group 3, 4 and 5 were orally injected GutGard™ at 15, 30 and 60 mg/kg, respectively, once daily 6 times/week for 8 weeks. (B) Time-points of *H. pylori* infection and GutGard™ treatment in C57BL/6 mice. Mice in Groups 2 and 3 were orally administered *H. pylori* (2×10^9 colony-forming units (CFU)) three times over 5 days. After *H. pylori* inoculation, mice in Group 3 were orally injected 25 mg/kg GutGard™ once daily 6 times/week for 3 weeks.

Detection of *H. pylori* colonization

The presence of *H. pylori* in gastric mucosa was confirmed by direct bacterial culture, as described previously (25). For culturing, the tissue was rubbed across the surface of a plate with selective medium containing 10% bovine serum, 6 µg/mL vancomycin, 5 µg/mL trimethoprim, 10 µg/mL polymyxin B, 200 µg/mL bacitracin, 8 µg/mL amphotericin B and 10 µg/mL nalidixic acid. Plates were incubated at 37°C under microaerophilic conditions for 5~7 days. Quantitative assessment of *H. pylori* colonization was performed as previously described (26). Briefly, one piece of weighed stomach tissue was homogenized in 200 µL of Brucella broth by use of a hand homogenizer (Pellet Pestle® Cordless Motor, Kontes, City, NJ, USA), and the homogenate was diluted 10- and 100-fold in Brucella broth. Fifty microliters of each dilution was plated on selective medium containing the antibiotics mentioned above. Plates were incubated at 37°C under microaerophilic conditions for 5~7 days. *H. pylori* strain was identified by gram staining and positive urease and catalase tests. *H. pylori* colonies were then counted to determine the number of CFU of the whole stomach tissue.

Enzyme-linked immunosorbent assay (ELISA)

Blood was collected from the heart immediately before the Mongolian gerbils were killed. The level of *H. pylori* in serum was measured by ELISA kit (MBS702763, MyBioSource, San Diego, CA, USA). The ELISA plates were coated with 100 µL of positive control, negative control or samples per well for 30 min at 37°C. The wells were washed with wash buffer and incubated for

30 min at 37°C with 100 µL/well HRP-conjugate working solution. The plates were washed and then further incubated for 10 min with 90 µL of TMB substrate. The reaction was stopped by adding 50 µL of stop solution. The absorbance at 450 nm was measured using a 96-well plate reader within 15 minutes. For calculating the valence of *H. pylori* antibody (IgG), the absorbance of sample well is compared with control: $OD_{\text{sample}} \geq 2.1 \times OD_{\text{negative}}$ was *H. pylori* positive, while $OD_{\text{sample}} < 2.1 \times OD_{\text{negative}}$ was negative.

Histopathological examination

The stomach tissue samples of Mongolian gerbils were fixed in 10% buffered formaldehyde, embedded in paraffin, and then sectioned. The 4~5 µm-thick sections were stained with hematoxylin and eosin (H&E) for histology observation. For H&E staining, the sections were stained with hematoxylin for 3 min, washed, and then stained with 0.5% eosin for 3 min. After washing with water, the slides were dehydrated in 70%, 96% and 100% ethanol, and then in xylene.

Immunohistochemistry

Immunohistochemical identification of *H. pylori* was done with the sections of the Mongolian gerbil's stomach tissue after deparaffinization. Microwave antigen retrieval was performed in citrate buffer (pH 6.0) for 10 min prior to peroxidase quenching with 3% hydrogen peroxide (H_2O_2) in PBS for 10 min. The sections were then washed in water and preblocked with normal goat or horse serum for 10 min. Next, the tissue sections were incubated overnight at 4°C in 1 : 100 dilutions of

anti-*H. pylori* antibody (Abcam Technologies, Cambridge, UK). The sections were then incubated with biotinylated secondary antibodies (1 : 200) for 1 h. After washing with PBS, streptavidin-HRP was applied. Finally, the sections were developed with diaminobenzidine tetrahydrochloride substrate for 10 min, and counterstained with hematoxylin. At least three random fields of each section were examined at a magnification of 200× and analyzed by Microsystem (Leica SCN400, Leica, Heidelberg, Germany).

Statistical analysis

Data were expressed as mean±SE. Comparison of groups of animals was undertaken using SPSS statistic 19 and *P*

values were set at level *P*<0.05. Statistical calculations were performed using SPSS software for the MS Windows operating system (Version 19; SPSS, IBM, Chicago, IL, USA).

RESULTS AND DISCUSSION

Previous reports have suggested that *H. pylori* eradication at an early stage might increase the success rate of reducing colonization and be effective for preventing gastric carcinogenesis (27). Research on anti-adhesive compounds has shown that extracts from several plants, including turmeric, parsley, borage, ginseng, worm-

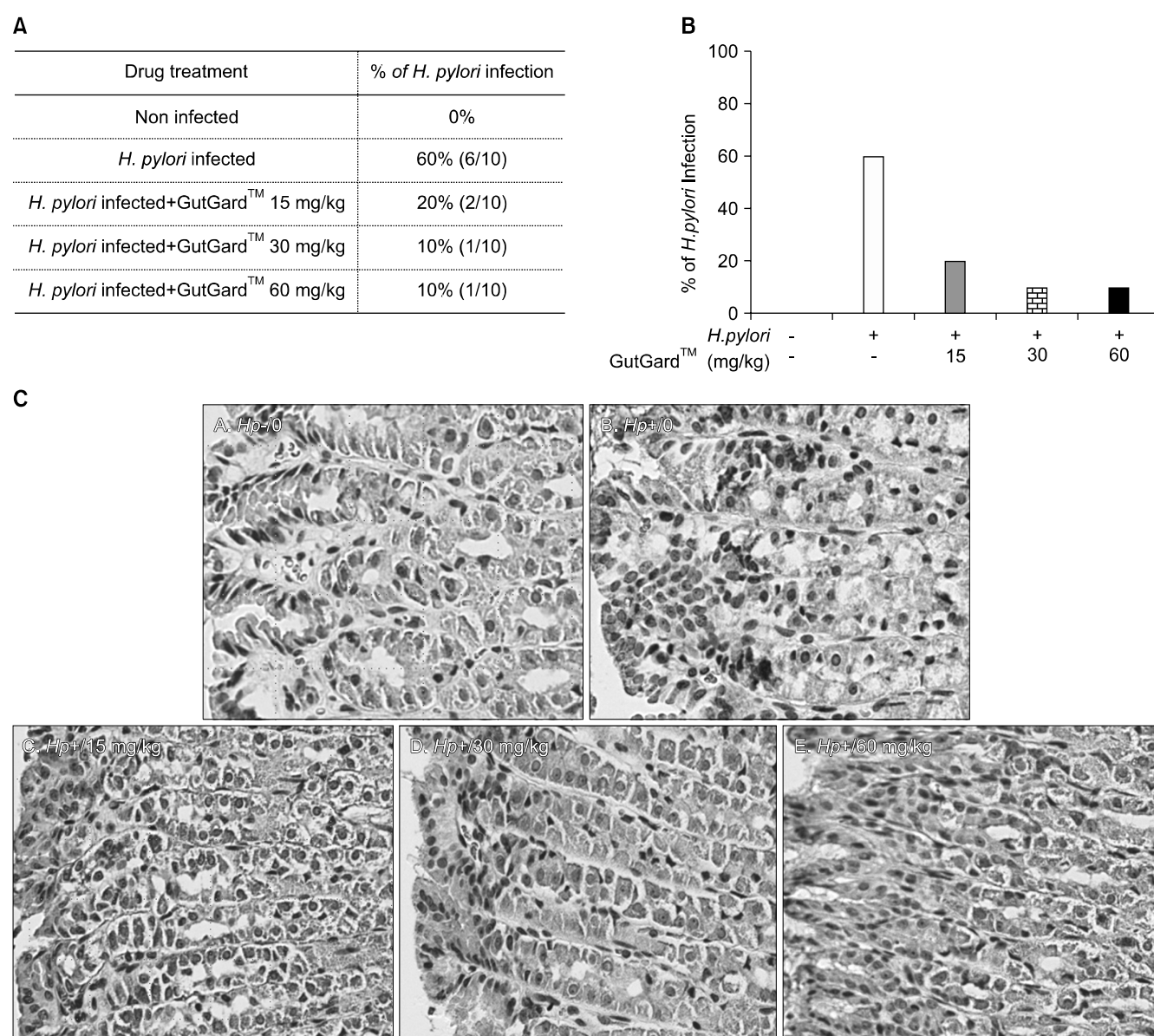


Fig. 2. Anti-*Helicobacter pylori* activity of GutGard™ in Mongolian gerbils. (A) *H. pylori* activity was assayed by ELISA in serum. The serums from gerbils were diluted 1 : 10 and then measured by ELISA. (B) Histogram of Panel A. (+), positive; (-), negative. (C) Representative Immunohistochemistry (IHC) of gerbil stomach tissue. After the final treatment of GutGard™, gerbil stomach tissues were removed, fixed and gastric mucosa was stained with *H. pylori* antibody. (*Hp*-), *H. pylori*-uninfected; (*Hp*+), *H. pylori*-infected gerbils with or without GutGard™ treatment.

wood, and cranberry, can inhibit adhesion of *H. pylori* to stomach sections (14,28,29). Recent studies have shown that the *Glycyrrhiza glabra* aqueous extract possesses antibacterial effect against *H. pylori*, which was confirmed *in situ* and *in vitro* (16).

In the present study, we examined anti-*H. pylori* activity of GutGard™ with the established models of *H. pylori* SS1 infection in Mongolian gerbils (30) and C57BL/6 mice (24).

Anti-*H. pylori* activity of GutGard™ in Mongolian gerbils

In order to assess the anti-*H. pylori* activity of GutGard™, we tested the effect of GutGard™ on the *H. pylori* colonization in Mongolian gerbils. Eight weeks after GutGard™ treatment (Fig. 1A), gerbils were sacrificed, and the stomachs were removed and embedded in paraffin for histological observation and immunohistochemical detection of *H. pylori*. Throughout the experiment, no statistically significant difference in the body weights was found in both uninfected groups and *H. pylori*-infected groups. The gastric mucosa of Mongolian gerbils did not present any significant signs of inflammation in the entire group. Immunohistochemistry stains showed no detectable *H. pylori* in uninfected control group but numbers of bacteria on the surface of mucosa in *H. pylori*-infected group (Fig. 2C). In contrast, eight weeks following GutGard™ treatment, the level of *H. pylori* colonization in the stomachs of gerbils was notably decreased.

We next measured the serum level of anti-*H. pylori* IgG antibody by ELISA. As shown in Fig. 2A and 2B, the serum from uninfected control group did not show any signs of *H. pylori* and 60% (6/10) of gerbils of infected group showed a positive level of *H. pylori* reaction. On the other hand, the gerbils orally treated with 15, 30 and 60 mg/kg GutGard™ displayed its positive reaction in 20% (2/10), 10% (1/10) and 10% (1/10), respectively. Treatment with GutGard™ for 8 weeks inhibited *H. pylori* infection in a dose-dependent manner, reaching 67% at 15 mg/kg and 83% at 30 and 60 mg/kg. Such anti-*H. pylori* activities of GutGard™ seem to be higher than the effect of green tea extract that exhibited 72% anti-*H. pylori* activity at 2,000 ppm in a gerbil model (31). Based on these results, it shows that oral treatment of GutGard™ can reduce the infection of *H. pylori* SS1 gastric mucosa.

Effects of the GutGard™ against *H. pylori* colonization in C57BL/6 mice

In a previous study, Raghavan et al. (32) reported that the colonization of C57BL/6 mice with *H. pylori* SS1 was stable after the first week and the minimum time needed for optimal colonization was 2 weeks. In addition, they observed that a marked difference in bacterial colo-

nization between male and female mice, in which the male mice consistently exhibited greater colonization (two- to three-fold). This encouraged us to test the early-stage of GutGard™ efficacy for suppressing *H. pylori* colonization in C57BL/6 male mice.

The animals were sacrificed 3 weeks after *H. pylori* infection and treatment with GutGard™ (Fig. 1B). Stomachs were removed and analyzed by direct and quantitative culture of *H. pylori*. The colonies grown from the selective medium were identified as *H. pylori* by gram staining, urease and catalase activities. In the infected (G2) group, all animals were successfully colonized by *H. pylori*, but no *H. pylori* colonies were detected in uninfected control (G1) group. In contrast, as shown in Fig. 3, the ability of *H. pylori* strain SS1 to colonize the gastric mucosa was significantly decreased in 25 mg/kg GutGard™-treated (G3) mice as compared to mice from the infected non-treated (G2) group (5.458 ± 0.065 Log CFU vs 6.042 ± 0.097 Log CFU, $P < 0.05$). Also, no toxic effects or changes in body weight were observed due to the GutGard™ treatment.

A recent study by Iimuro et al. (33) suggests that garlic extract may suppress the early stage of *H. pylori*-induced gastritis. However, the average number of viable bacteria (log (CFU/stomach)) from all animals of the *H. pylori*-infected control and garlic extract groups showed no significant differences. From our present observations, the oral treatment of GutGard™ for 3 weeks just after the final *H. pylori* infection could reduce *H. pylori* SS1 gastric colonization in a significant proportion of mice ($P < 0.05$).

In conclusion, GutGard™ may possess significant anti-*H. pylori* properties against *H. pylori* SS1 both in Mongolian gerbils and C57BL/6 mice. On the other hand, deglycyrrhized root extract of *Glycyrrhiza glabra* may

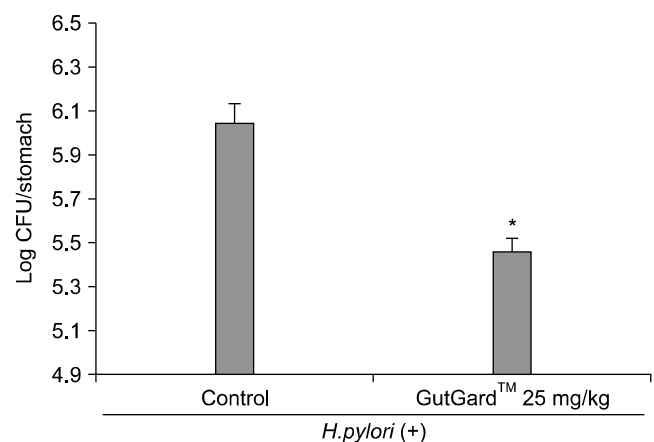


Fig. 3. Effects of GutGard™ against *H. pylori* colonization in C57BL/6 mice. GutGard™ was given at 25 mg/kg/dose, once daily 6 times/week for 3 weeks. The results are expressed as mean ± SE (n=10). $P < 0.05$ shows statistical difference. *Compared with vehicle control.

have potential as a very safe resource to control *H. pylori*-associated gastric disease.

ACKNOWLEDGMENTS

This research was supported by the grants from Korean Health Industry Development Institute (KHIDI) and also by National Center of Efficacy Evaluation for the Development of Health Products Targeting Digestive Disorders (NCEED).

AUTHOR DISCLOSURE STATEMENT

The authors declare no conflict of interest.

REFERENCES

1. Marshall JB. 2001. One hundred years of discovery and rediscovery of *Helicobacter pylori* and its association with peptic ulcer disease. In *Helicobacter pylori: Physiology and Genetics*. Mobley HLT, Mendz GL, Hazell SL, eds. ASM Press, Washington, DC, USA. p 19-24.
2. Hunt RH, Xiao SD, Megraud F, Leon-Barua R, Bazzoli F, Van der Merwe S, Vaz Coelho LG, Fock M, Fedail S, Cohen H, Malfertheiner P, Vakil N, Hamid S, Goh KL, Wong BCY, Krabshuis J, Le Mair A. 2011. *Helicobacter pylori* in developing countries. *J Gastrointestin Liver Dis* 20: 299-304.
3. Nomura A, Stemmermann GN, Chyou PH, Perez-Perez GI, Blaser MJ. 1994. *Helicobacter pylori* infection and the risk for duodenal and gastric ulceration. *Ann Intern Med* 120: 977-981.
4. Adamu MA, Schottker B, Weck MN, Brenner H. 2012. *Helicobacter pylori* infection is strongly associated with gastric and duodenal ulcers in a large prospective study. *Clin Gastroenterol Hepatol* 10: 487-493.
5. Fuccio L, Zagari RM, Eusebi LH, Laterza L, Cennamo V, Ceroni L, Grilli D, Bazzoli F. 2009. Meta-analysis: can *Helicobacter pylori* eradication treatment reduce the risk for gastric cancer? *Ann Intern Med* 151: 121-128.
6. Montalban C, Castrillo MJ, Abaira V, Serrano M, Bellas C, Piris MA, Carrion R, Cruz MA, Laraña JG, Menarguez J, Gomez-Marcos F, Rivas C. 1995. Gastric B-cell mucosa-associated lymphoid tissue (MALT) lymphoma. Clinicopathological study and evaluation of the prognostic factors in 143 patients. *Ann Oncol* 6: 355-362.
7. Owens SR, Smith LB. 2011. Molecular aspects of *H. pylori*-related MALT lymphoma. *Patholog Res Int* 2011: 193149.
8. Malfertheiner P, Megraud F, O'Morain C, Bazzoli F, El-Omar E, Graham D, Hunt R, Rokkas T, Vakil N, Kuipers EJ. 2007. Current concepts in the management of *Helicobacter pylori* infection: the Maastricht III Consensus Report. *Gut* 56: 772-781.
9. Chey WD, Wong BC. 2007. American College of Gastroenterology guideline on the management of *Helicobacter pylori* infection. *Am J Gastroenterol* 102: 1808-1825.
10. Fischbach L, Evans EL. 2007. Meta-analysis: the effect of antibiotic resistance status on the efficacy of triple and quadruple first-line therapies for *Helicobacter pylori*. *Aliment Pharmacol Ther* 26: 343-357.
11. De Francesco V, Giorgio F, Hassan C, Manes G, Vannella L, Panella C, Ierardi E, Zullo A. 2010. Worldwide *H. pylori* antibiotic resistance: a systematic review. *J Gastrointestin Liver Dis* 19: 409-414.
12. Basset C, Holton J, Gatta L, Ricci C, Bernabucci V, Liuzzi G, Vaira D. 2004. *Helicobacter pylori* infection: anything new should we know? *Aliment Pharmacol Ther* 2: 31-41.
13. Mégraud F. 2004. *H. pylori* antibiotic resistance: prevalence, importance, and advances in testing. *Gut* 53: 1374-1384.
14. O'Mahony R, Al-Khtheeri H, Weerasekera D, Fernando N, Vaira D, Holton J, Basset C. 2005. Bactericidal and anti-adhesive properties of culinary and medicinal plants against *Helicobacter pylori*. *World J Gastroenterol* 11: 7499-7507.
15. Lata S, Kakkar S, Srivastava VK, Saxena KK, Saxena RS, Kumar A. 1999. Comparative antipyretic activity of *Ocimum sanctum*, *Glycyrrhiza glabra* and aspirin in experimentally-induced pyrexia in rats. *Indian J Pharmacol* 31: 71-75.
16. Wittschier N, Faller G, Hensel A. 2009. Aqueous extracts and polysaccharides from liquorice roots (*Glycyrrhiza glabra* L.) inhibit adhesion of *Helicobacter pylori* to human gastric mucosa. *J Ethnopharmacol* 125: 218-223.
17. Dong S, Inoue A, Zhu Y, Tanji M, Kiyama R. 2007. Activation of rapid signaling pathways and the subsequent transcriptional regulation for the proliferation of breast cancer MCF-7 cells by the treatment with an extract of *Glycyrrhiza glabra* root. *Food Chem Toxicol* 45: 2470-2478.
18. Gupta VK, Fatima A, Faridi U, Negi AS, Shanker K, Kumar JK, Rahuja N, Luqman S, Sisodia BS, Saikia D, Darokar MP, Khanuja SP. 2008. Antimicrobial potential of *Glycyrrhiza glabra* roots. *J Ethnopharmacol* 116: 377-380.
19. Lakworthy W, Holgate PF. 1975. Deglycyrrhizinized liquorice in the treatment of chronic duodenal ulcer. A retrospective endoscopic survey of 32 patients. *Practitioner* 215: 787-792.
20. Feldman RA. 2001. Epidemiologic observations and open questions about disease and infection caused by *Helicobacter pylori*. In *Helicobacter pylori: Molecular and Cellular Biology*. Achtman M, Suerbaum S, eds. Horizon Scientific Press, Wymondham, United Kingdom. p 29-51.
21. Chandrasekaran CV, Sundarajan K, Gupta A, Srikanth HS, Edwin J, Agarwal A. 2011. Evaluation of the genotoxic potential of standardized extract of *Glycyrrhiza glabra* (GutGard™). *Regul Toxicol Pharmacol* 61: 373-380.
22. Raveendra KR, Jayachandra, Srinivasa V, Sushma KR, Allan JJ, Goudar KS, Shivaprasad HN, Venkateshwarlu K, Geetharani P, Sushma G, Agarwal A. 2012. An extract of *Glycyrrhiza glabra* (GutGard) alleviates symptoms of functional dyspepsia: a randomized, double-blind, placebo-controlled study. *Evid Based Complement Alternat Med* 2012: 216970.
23. Mukherjee M, Bhaskaran N, Srinath R, Shivaprasad HN, Allan JJ, Shekhar D, Agarwal A. 2010. Anti-ulcer and anti-oxidant activity of GutGard. *Indian J Exp Biol* 48: 269-274.
24. Golden SA, Covington HE 3rd, Berton O, Russo SJ. 2011. A standardized protocol for repeated social defeat stress in mice. *Nat Protoc* 6: 1183-1191.
25. Hernández F, Rivera P, Sigarín M, Miranda J. 1991. Diagnosis of *Helicobacter pylori*: comparison of a urease test, histological visualization of curved bacteria and culture. *Rev Inst Med Trop Sao Paulo* 33: 80-82.
26. Ddd Li GQ, Xia HH, Chen MH, Gu Q, Wang JD, Peng JZ, Chan AOO, Cho CH, So HL, Lam SK, Hu PJ, Liang YJ, Lin HL, Berg DE, Feng ZH, Langenbach R, Wong BCY. 2006. Effects of cyclooxygenase-1 and -2 gene disruption on *Helicobacter pylori*-induced gastric inflammation. *J Infect Dis* 193: 1037-1046.
27. Nozaki K, Shimizu N, Ikehara Y, Inoue M, Tsukamoto T, Inada K, Tanaka H, Kumagai T, Kaminishi M, Tatematsu M. 2003. Effect of early eradication on *Helicobacter pylori*-related gastric carcinogenesis in Mongolian gerbils. *Cancer Sci* 94: 235-239.

28. Lee JH, Park EK, Uhm CS, Chung MS, Kim KH. 2004. Inhibition of *Helicobacter pylori* adhesion to human gastric adenocarcinoma epithelial cells by acidic polysaccharides from *Artemisia capillaris* and *Panax ginseng*. *Planta Med* 70: 615-619.
29. Shmueli H, Burger O, Neeman I, Yahav J, Samra Z, Niv Y, Sharon N, Weiss E, Athamna A, Tabak M, Ofek I. 2004. Susceptibility of *Helicobacter pylori* isolates to the anti-adhesion activity of a high-molecular-weight constituent of cranberry. *Diagn Microbiol Infect Dis* 50: 231-235.
30. Ikeno T, Ota H, Sugiyama A, Ishida K, Katsuyama T, Genta RM, Kawasaki S. 1999. *Helicobacter pylori*-induced chronic active gastritis, intestinal metaplasia, and gastric ulcer in Mongolian gerbils. *Am J Pathol* 154: 951-960.
31. Matsubara S, Shibata H, Ishikawa F, Yokokura T, Takahashi M, Sugimura T, Wakabayashi K. 2003. Suppression of *Helicobacter pylori*-induced gastritis by green tea extract in Mongolian gerbils. *Biochem Biophys Res Commun* 310: 715-719.
32. Raghavan S, Hjulström M, Holmgren J, Svennerholm AM. 2002. Protection against experimental *Helicobacter pylori* infection after immunization with inactivated *H. pylori* whole-cell vaccines. *Infect Immun* 70: 6383-6388.
33. Iimuro M, Shibata H, Kawamori T, Matsumoto T, Arakawa T, Sugimura T, Wakabayashi K. 2002. Suppressive effects of garlic extract on *Helicobacter pylori*-induced gastritis in Mongolian gerbils. *Cancer Lett* 187: 61-68.